

## The Fundoscopic Exam

A funduscopy, also known as ophthalmoscopic, retinal, or funduscopy exam, is a test used to screen for eye disorders, injuries, and diseases. It can be one of the more challenging procedures performed during both routine physical examinations and emergency care evaluations.

### Anatomy Review

The retina is the layer of cells lining the back wall inside the eye (fundus) that senses light and sends signals to the brain (American Academy of Ophthalmology, n.d.). The retina is the only part of the central nervous system that can be viewed from outside of the body and the fundus is the singular part of the body where vessels can be directly visualized (Stanford Medicine, n.d.). Health care providers use funduscopy to screen for eye conditions such as:

- Damage to the optic nerve
- Retinal tear or detachment
- Glaucoma
- Macular degeneration
- Cytomegalovirus (CMV) retinitis (infection of the retina)
- Ocular melanoma or melanoma that spreads to the eye
- Hypertension
- Diabetes

### Equipment Review (Stanford Medicine, n.d.)

To perform funduscopy, you'll need an ophthalmoscope. Direct ophthalmoscopes are small, hand-held instruments equipped with a concave mirror, light source, eye piece, and handle. The light reflects off the retina and back through a hole in the ophthalmoscope, providing the clinician with a magnified image of the anatomy at the back of the eye. Indirect ophthalmoscopes include monocular and binocular scopes. These are more sophisticated instruments typically used by ophthalmic specialists. Direct ophthalmoscopes include the following parts.

- Lens (focusing) wheel:
  - Increasing the green (positive) numbers on the dial will focus close objects.
  - Increasing the red (negative) numbers on the dial will focus far objects.
- Light source: ophthalmoscopes have 2 or 3 sizes of light that are selected based on the size of the pupil and amount of light in the room.
  - Small light for a very constricted pupil in a well-lit room
  - Medium light for a non-dilated pupil in a dark room
  - Large light used if pupils are dilated with mydriatic drops
- Half light setting: used when the pupil is partly obscured by cataracts of the lens; allows light to pass through the clear part of the pupil.
- Aperture/filter dial
  - Red free setting: helps view vessels and hemorrhages by enhancing contrast; the image will appear black and white.
  - Slit beam: used to inspect contour abnormalities of the cornea, lens, and retina.

- Blue Light: used to inspect corneal abrasions and ulcers after fluorescein staining.
- Grid: used to approximate space between retinal lesions.

### Performing Fundoscopy (Stanford Medicine, n.d.; Bickley et al., 2021)

Developing a consistent approach to fundoscopic examinations will improve the speed and efficiency with which you are able to perform this procedure. The eyes may be examined without dilating the pupils using an ophthalmoscope. However, pupil dilation with mydriatic drops will help visualize more peripheral structures, the macula and evaluate unexplained visual loss. The following procedure focuses on the use of a traditional direct ophthalmoscope.

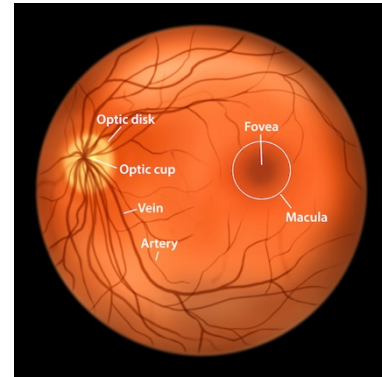
1. Ask the patient to remove their eyeglasses. Contact lenses may remain in place.
2. Dim the lights, however the room shouldn't be completely dark.
3. Explain the procedure to the patient.
4. Patient should be in an upright sitting position.
5. Turn the focusing wheel to the 0 diopter, where the lens neither converges nor diverges light.
6. Hold the scope in your right hand, keeping your finger on the edge of the lens disc to turn the focusing wheel. Place the scope up to your right eye and press it against your right cheek. Tilt the handle laterally about 20 degrees slant from vertical. Rest your other hand on the patient's head with your thumb on the patient's right eyebrow.
7. Ask the patient to look slightly up and over your shoulder and focus on a specific point about 3 feet away or at a point directly ahead on the wall.
8. Position yourself about 15 inches away from the patient and at an angle 15 degrees lateral to the patient's line of vision. Look through the ophthalmoscope into the patient's right eye. Keep your other eye open and look for the orange glow in the pupil – the red reflex. Note any opacities that obscure the red reflex.
9. Place the thumb of your other hand across the patient's eyebrow to steady your examining hand. Keeping the light beam focused on the red reflex, move in with the ophthalmoscope on the 15-degree angle toward the pupil until you are very close to it, almost touching the patient's eyelashes. Then follow the red reflex medially (toward the nose) until you see the retina.
10. You should see the optic disc. If out of focus, adjust the lens dial up or down until you achieve focus.
11. Move the light around the retina until you have visualized all areas. Ask the patient to look directly into the light to view the macula last.
12. Repeat procedure with the left eye.

Mydriatic (pupil dilating) drops may be used to facilitate the procedure, typically in specialized ophthalmology settings. If dilating drops will be used, inform that patients that they'll need someone to drive them home. Ask the patient to report an inability to regain accommodation (focus) within two hours after the procedure. They should also report any eye pain or unusual headache that day.

### Normal Anatomical Landmarks

Once you master the ability to view the retina, work on observing these normal anatomical landmarks.

- **Optic disc** – yellow-orange to creamy pink in color with a rim that stands out from the red/orange background; this is the optic nerve head. It measures 1.5 mm but is magnified 15 times by the scope. Adjust the focusing wheel to sharpen the focus of the optic disc. The retina is typically in focus at 0 diopters.
- **Optic cup** – pale yellow-white, central area of the optic disc, normally less than half to one-third the diameter of the optic disc.
- **Macula** – dark spot on the retinal surface free from arteries or veins. It is responsible for central vision and is comprised of the fovea and perifovea areas. Light reflections in the macular area are common.
- **Fovea** – central area of the macula; better seen with a red-free filter and is typically 2 disc diameters away from the optic disc. It is responsible for high-acuity vision.
- **Vessels**
  - Start at the disc and follow the vessels out inspecting for hypertensive and arteriosclerotic changes.
  - Central retinal artery branches off the optic nerve. Arteries are smaller, narrower ( $\frac{2}{3}$  to  $\frac{3}{4}$  diameter of veins), and lighter in color. The light reflex (reflection) is bright.
  - Central retinal vein branches off the optic nerve and appears pulsating. The light reflex will be minimal or absent.
  - The vessel size becomes progressively larger at each branch point as you approach the disc.
  - Spontaneous venous pulsations (SVPs) are rhythmic variations in the retinal veins as they cross the fundus (narrow in systole; wider in diastole). SVPs are present in 90% of normal patients.
- Assess for any lesions on the retina and note their size, shape, color, and distribution.



### Abnormal Findings (Bickley et al., 2021)

- Swelling of the optic disc and anterior bulging of the optic cup suggest papilledema (optic nerve head swelling associated with increased intracranial pressure). Papilledema may be a sign of serious neurological disorders such as:
  - Meningitis
  - Subarachnoid hemorrhage
  - Trauma
  - Mass lesions
- An increased size in the optic cup may indicate chronic open-angle glaucoma.
- Increased intracranial pressure (above 190 mm Hg), glaucoma, and retinal vein occlusion may cause a loss of SVPs.
- An obscured red reflex may be caused by corneal scars, cataracts, vitreous hemorrhage or an artificial eye. A detached retina, mass or retinoblastoma (in children) may also obscure the red reflex.
- Superficial retinal hemorrhages are small, linear, red streaks in the fundi that may appear in clusters. May be seen in hypertension, papilledema, and occlusion of the retinal vein.

- Periretinal hemorrhages develop when blood escapes into the space between the retina and vitreous humor. It is anterior to the retina and obscures underlying retinal vessels. It is caused by a sudden increase in intracranial pressure.
- Deep retinal hemorrhages are small, rounded, slightly irregular red spots that occur in the deeper layer of the retina. Commonly caused by diabetes.
- Microaneurysms are tiny, round, red spots seen in and around the macular area. These are minute dilations of the small retinal vessels and a sign of diabetic retinopathy.
- Neovascularization (new vessels) on the optic disc are a sign of proliferative diabetic retinopathy. The vessels may grow into the vitreous humor causing retinal detachment or hemorrhage and possibly loss of vision.
- Cotton-wool spots are white or gray lesions with irregular “soft” borders caused by microinfarcts of the retinal nerve fiber. These may be seen in hypertension, diabetes, HIV and other viruses.
- Hard exudates are creamy or yellow, bright lesions with well-defined “hard” borders. They may be small and round or large irregular spots, often occurring in clusters or circular, linear, or star-shaped patterns. These lipid residues from damaged capillaries are caused by diabetes and vascular dysplasias.
- Dead retinal pigment cells or drusen on the surface of the retina may appear as “hard” and sharply defined or “soft” pigment changes on the macula. Presence of drusen may be seen in normal aging and age-related macular degeneration.

## PEARLS

- If structures are blurred on exam, rotate the focusing wheel until you find the sharpest focus.
  - If the patient is myopic (nearsighted), rotate the focusing wheel counterclockwise to the minus (red) diopters. Light rays will focus anterior to the retina. Retinal structures in a myopic eye look larger than normal.
  - If the patient is hyperopic (farsighted), move the focusing wheel clockwise to the plus (green) diopters. Light rays will focus posterior to the retina.
- As you examine the retina, move your head and scope as a unit.
- Retinal detachment is best viewed with pupils dilated under indirect funduscopy.

## References:

American Academy of Ophthalmology. (n.d.). Retina. *American Academy of Ophthalmology*. <https://www.aao.org/eye-health/anatomy/retina-103>

Bickley, L. S., Szilagy, P. G., Hoffman, R. M., & Soriano, R. P. (2021). *Bate's Guide to Physical Examination and History Taking* (13<sup>th</sup> ed.). Wolters Kluwer Health: Philadelphia.

Stanford Medicine. (n.d.) Introduction to the Fundoscopic/Ophthalmoscopic Exam. *Stanford Medicine* 25. <https://stanfordmedicine25.stanford.edu/the25/fundosopic.html>