

Breast Assessment

Introduction

Breast examination is an important aspect of the diagnosis, detection, and surveillance of breast diseases. Current guidelines for frequency of female clinical breast examination are outlined below. Patient reports of breast pain, lumps, nipple discharge, or gross changes in the size or shape of the breast warrant a clinical examination of the breast.

Focused breast assessment in males and females alike begins with taking a detailed health history. While doing so, observe carefully for nonverbal cues of discomfort or pain. Order of examination is performed as inspection followed by palpation. Explain the examination to the patient and include a chaperone due to the intimate nature of the examination.

Guidelines for Clinical Breast Examination

The National Comprehensive Cancer Network screening guidelines suggest that women between 25 and 40 years old who are asymptomatic and have no special risk factors for breast cancer undergo a clinical breast exam every 1 to 3 years. Women older than age 40, women with increased risk factors for breast cancer, history of breast cancer, and/or symptomatic patients are recommended to receive more frequent clinical breast exams (Bever et al, 2018).

The American Congress of Obstetricians and Gynecologists recommends offering a clinical breast exam for average-risk women aged 25 to 39 every 1-3 years, and an annual breast exam to women aged over 40 years (Pearlman, 2017).

The American Cancer Society does not recommend regular clinical breast exams for cancer screening for women in any risk group. It does state, however, that all women should pay attention to the typical appearance and texture of their breasts and report any changes to their doctor right away (American Cancer Society, 2023).

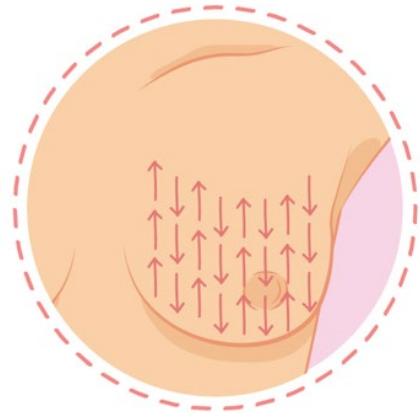
Optimal Patient Gowning/Positioning

- Patient should be provided privacy to change into an open-front gown, with a large drape or sheet to assist with appropriate coverage.
- Breasts should only be exposed as necessary. For instance, both are required to be visualized for symmetry, but when examining the right breast, the left breast should be covered for patient comfort.
- Examine the patient first in a seated position, and then supine position.

Exam methods

- **Breast inspection**
 - With the patient seated and arms at sides, visualize both breasts noting the skin color, any rashes or lesions, skin thickness, size, and symmetry. In males, gynecomastia may be identified.

- Observe breast contour, including dimpling, masses, or flattening.
- Inspect the nipples and areolae for discharge, size, shape, inversion, or lesions.
- Ask the patient to raise the arms over the head, place hands on hips, and lean forward to observe for any dimpling or change in contour.
- **Breast palpation**
 - Examine the patient in a supine position with the ipsilateral arm raised to rest on the forehead or behind the patient's head.
 - A vertical strip pattern is the best technique for evaluating for breast masses. Palpate using the pads of the second, third, and fourth fingers, keeping the fingers slightly flexed, in small concentric circles applying ascending pressure to each area. Starting at the axilla, work in a vertical pattern, moving inward to the midline. Once the nipple line is reached, the patient should place the ipsilateral hand on that same shoulder with the elbow at the level of the shoulder for best positioning, as the assessment continues to the medial breast. It is important to be systematic.
 - The examiner should note the consistency of the tissues, tenderness, lesions, or nodules. Location of any nodules or masses should be described in a clock pattern or quadrant.
 - Palpate each nipple, noting the color, consistency, and quantity of any discharge and exactly where it appears.
- **Axilla inspection and palpation**
 - While patient is supine, inspect the axilla for excoriation, lesions, or rashes.
 - Palpate for masses, nodules, and lymphadenopathy. The patient's arm should be relaxed at his/her side and the examiner cups his/her fingers, reaching as far into the axilla as possible reaching behind the pectoral muscle to palpate the lymph nodes. To do so, use your right hand to examine the left axilla, and the left hand to examine the patient's right. The patient should be advised that this examination may be uncomfortable.



PEARLS

- Female breasts contain hormonally sensitive tissue, with uneven texture known as physiologic nodularity. Male breasts lack the development of ductal branching and lobules, making it difficult to discern from pectoral muscle tissue.
- Palpating the breast tissue while the patient is supine is helpful as the tissue flattens out.
- While performing the breast assessment, teach and reinforce the importance of breast self-exams.

References:

American Cancer Society. (2023, December 19). American cancer society recommendations for the early detection of breast cancer. <https://www.cancer.org/cancer/types/breast-cancer/screening-tests-and-early-detection/american-cancer-society-recommendations-for-the-early-detection-of-breast-cancer.html>

Bever, T. B., Helvie, M., Bonaccio, E., Calhoun, K. E., Daly, M. B., Farrar, W. B., Garber, J. E., Gray, R., Greenberg, C. C., Greenup, R., Hansen, N. M., Harris, R. E., Heerdt, A. S., Helsten, T., Hodgkiss, L., Hoyt, T. L., Huff, J. G., Jacobs, L., Lehman, C. D., Monsees, B., ... Kumar, R. (2018). Breast Cancer Screening and Diagnosis, Version 3.2018, NCCN Clinical Practice Guidelines in Oncology. *Journal of the National Comprehensive Cancer Network: JNCCN*, 16(11), 1362–1389. <https://doi.org/10.6004/jnccn.2018.0083>

Bickley, L. S., Szilagyi, P. G., Hoffman, R. M., & Soriano, R. P. (2021). *Bate's Guide to Physical Examination and History Taking* (13th ed.). Wolters Kluwer Health: Philadelphia.

Pearlman, M. (2017). American College of Obstetrics and Gynecology Breast Cancer Risk Assessment and Screening in Average-Risk Women. *Practice Bulletin*, Number 179 <https://www.acog.org/clinical/clinical-guidance/practice-bulletin/articles/2017/07/breast-cancer-risk-assessment-and-screening-in-average-risk-women>